

Wounds

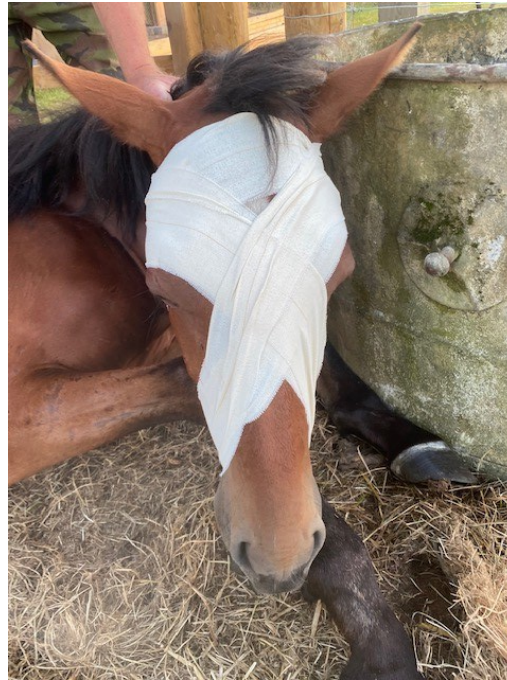If you have a horse, pony or donkey at some point you are likely to have to respond to a wound. This may be a mild abrasion to a severe laceration.

At Summerleaze we are always available to attend wounds as needed or, provide advice over the phone.



Wounds that require urgent veterinary care

- + Wounds close to joints
- + Wounds associated with a horse's eye
- + Wounds with uncontrollable bleeding
- + Wounds where underlying structures are visible such as bone or tendon
- + Penetrating wounds for example with sticks or nails
- + Wounds associated with lameness
- + Wounds near to eyes
- + Wounds associated with significant bleeding
- + Wounds associated with swelling
- + Any wound you are concerned about!



Whilst waiting for a vet

If it is safe to do so you can start cleaning the wound with water and if bleeding, pressure can be applied to the wound with a clean bandage.

Please do not apply purple spray, or similar, whilst waiting for a vet as it can make it harder to assess the wound.



To stitch or not to stitch

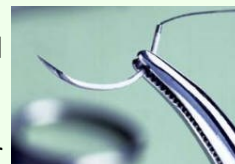Not all wounds require stitching. They may be too shallow, the skin could be under too much pressure, or, if the wound is over somewhere highly moveable, for example the fetlock, to give you just a few scenarios.

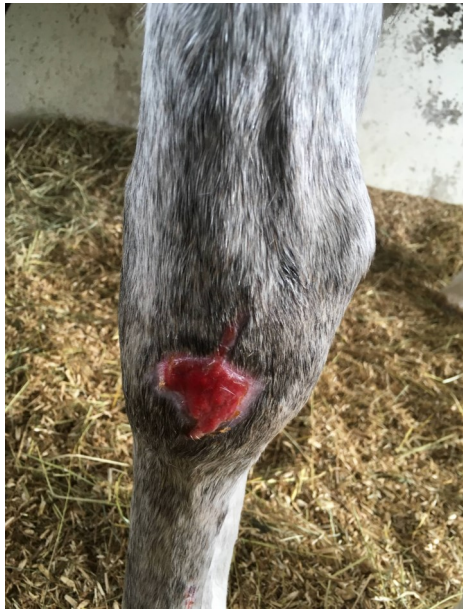The ideal time to stitch a wound is within 6 hours of the wound occurring, but, there is still potentially an option up to 12 hours.

If the wound is older than that it is unlikely to be a candidate for suturing. We may choose to do a secondary closure later, on an older wound to aid healing but, this would be on a case by case basis.

If there is a worry that the wound may be heavily contaminated, it would also not be a candidate for suturing.

Some wounds may also require closure under general anaesthetic.





Proud Flesh

Proud flesh is the term used for excessive granulation tissue; the skin is unable to grow over the top of this tissue, preventing complete wound closure.

It is most commonly a feature on wound areas that are highly mobile, such as distal limbs and also, in wounds that have had issues with infection.

It can occur in wounds that have been left open, that, ideally should initially have been sutured or bandaged. It is often treated by surgical debridement as there are no nerves present in this tissue so it is painless to remove .

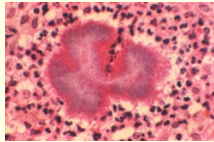


Cellulitis, why do some wounds cause it and why is it such an issue?

Cellulitis is a bacterial infection that results in a painful swelling, heat and lameness of the horse's leg. It can also cause the horse to become in-appetent and to have an increased temperature.

Whilst commonly associated with leg wounds, cellulitis can affect any part of the horse's body. It can require aggressive medical treatment to get rid of, but typically treatment starts with antibiotics, anti inflammatories, gentle exercise, cold hosing and bandaging may also be advised.

It only requires a small number of bacteria to gain entry through the wound to cause cellulitis. Blunt trauma can also be a cause, so you may not even find a break in the skin. Unfortunately, once a horse has had cellulitis, they are more likely to develop it again. In rare circumstances cellulitis can also cause laminitis as the horse is at risk initially from septic laminitis if the bacteria travel to the feet and from weight bearing laminitis if the horse is too painful to stand on the affected leg in the opposite leg. There is also a risk of dermal necrosis where the skin over the cellulitis dies away due to blood supply becoming compromised or a direct result of toxin production in the area. In some extreme cases the damage to a leg caused by cellulitis can result in long term lameness. Colic is also a risk in horses with cellulitis as anything that may stop a horse behaving normally in terms of eating, drinking and moving around can predispose them to colic.



Small wounds and lameness

It is important to call a vet if your horse is very lame, as it can suggest there might be the involvement of other internal structures such as joints, tendons or bones.

For example a kick from another horse may only have caused a mild wound but underneath it might have a fracture. Equally if the horse is still lame post, what might have appeared as a small injury, may be indicative of a larger underlying issue. Radiographs or ultrasound investigation help to identify the true extent of the damage.

The use of hibiscrub or iodine to clean wounds

It is perfectly acceptable to use either dilute hibiscrub or dilute iodine to clean minor wounds (major wounds should have a vet attend).

It is important that wounds are cleaned as soon as they are discovered to reduce the risk of infection.

If it is safe to do so it is also advisable to clip around minor wounds to help keep them clean.

Please do not to use hibiscrub on wounds around your horse's eyes as this can be a major irritant.



In other news...

We would like to take this opportunity to introduce to you and welcome, two new members to our vet team!

Antonia Evans and Laura Freeman joined us in October, but are both proving to be photo shy! Please keep an eye on our Facebook page and website .